

## **A NOVEL IMAGE PROCESSING SCHEME TO EVALUATE BREAST THERMAL IMAGES**

N. SRI MADHAVA RAJA\*, DEEPTI SURESH, A. KIRTHINIGODWEENA

Department of Electronics and Instrumentation Engineering,  
St. Joseph's College of Engineering, Rajiv Gandhi Road, Chennai 600119, India  
\*Corresponding Author: nsrimadhararaja@stjosephs.ac.in

### **Abstract**

A substantial amount of procedures is available to examine the breast abnormality, such as cancer and Ductal Carcinoma In Situ (DCIS) in literature. This work proposes a novel image processing practice to investigate the breast abnormality recorded with thermal imaging procedure. It implements a pre-processing procedure based on the Kapur's multiple thresholding with level three and post-processing approach based on the watershed algorithm. In order to intensify the quality of pre-processing technique, recent heuristic algorithm called Social Group Optimization (SGO) is adopted. The proposed approach in this paper includes the subsequent stages: i) Tri-level thresholding based on the Kapur + SGO, ii) Edge detection based dimension analysis of left and right breast region to identify the abnormality, and iii) Watershed based segmentation to extract the DCIS region. The proposed technique is tested using the benchmark breast thermal dataset available at Visual lab. The investigational work is accomplished with the Matlab software. The results of this work endorse that, the proposed approach has improved efficacy in examining the breast thermal images when compared to conventional heuristic approaches. It extracts the initial changes of tissues when affected by diseases. The advantage of infrared images combined with SGO multi-thresholding method provides more vital information for early diagnosis.

Keywords: Breast cancer, Image evaluation, Kapur's entropy, Thermal image, Watershed algorithm.

## **1. Introduction**

The Breast malignancy is a life intimidating diseases for women society [1, 2]. Accessibility to the contemporary medical knowledge will help them to notice the irregular cell growth in breast section during screening. When the size and the orientation of the breast irregularity are documented, then it is possible for the doctors to plan for the appropriate treatment procedure to manage and to understand the prognosis of the illness [3].

The mainstream of breast cancer begins in section of the breast tissue. Primarily, it will be initiated in the soft tissues of the breast, and will grow to its neighboring regions. Generally the breast tumor is due to the irregular swelling in the breast tissues. Bejnordi et al. [4] reported that, almost 80% of the breast cancer happens in epithelial cells of these ducts. Identification of cancer in its preliminary stage will aid for early treatment procedure which will support for complete cure of the disease.

In literature, non-invasive imaging modalities, such as mammogram [5], Infrared Thermal Imaging (ITI) [2] and Magnetic Resonance Imaging (MRI) [6] are extensively used for registering the breast tumor during screening.

Mammogram and MRI are the frequent methods, broadly considered to identify the well-developed cancer. These methods may deliver poor results when the cancer is in its nascent stage. Further, exposure to radiation and procedure involved enhances disease prognosis and also causes discomfort. Hence, in recent years, ITI procedures are extensively used by the doctors to record and investigate the breast disease for early diagnosis [7-10]. In this process, the infrared radiation which is released by the skin periphery is received as a thermal map by a unique camera. The obtained heat outlines are further examined to identify the existing disease.

Literature delivers the particulars of considerable procedures to gauge the anomaly in the breast [3]. This work proposes a novel image examination practice is suggested to examine the benchmark breast thermal images existing in Visual lab database [11, 12]. It implements a pre-processing procedure for integration of the Social Group Optimization and Kapur's tri-level thresholding and the post-processing work implements the watershed algorithm based segmentation. In this work, the various types of images, such as normal, abnormal and abnormal images with DCIS are considered for the evaluation.

The proposed approach initially implements a tri-level thresholding procedure on the RGB scale thermal image. Later, an edge discovery process is performed to extract the breast region, to find the pixel similarity between the left side and right side breast. Symmetry based approach and combination of multi-threshold with SGO extracts early vital information of disease prognosis. The usage of this modality and proper processing would yield significant results for various diseases and particularly carcinoma. This procedure will help the user to confirm the abnormality in the breast section based on its size analysis. Finally, the watershed algorithm can be used to extract the abnormality, such as tumor and DCIS existing in the pre-processed image. All the investigations are realized with Matlab software. The results of this study confirms that, proposed approach has improved efficacy in identifying the breast abnormality based on the considered thermal images. In future, this proposed approach can be used to examine the real clinical images obtained from the clinics/hospitals.

## 2. Methodology

The overview of procedures considered is represented in Fig. 1. During the simulation process, the ITI dataset images of Visual lab [11, 12] are considered. Based on the abnormality, images of the considered images are clustered as normal, intermediate and abnormal images.

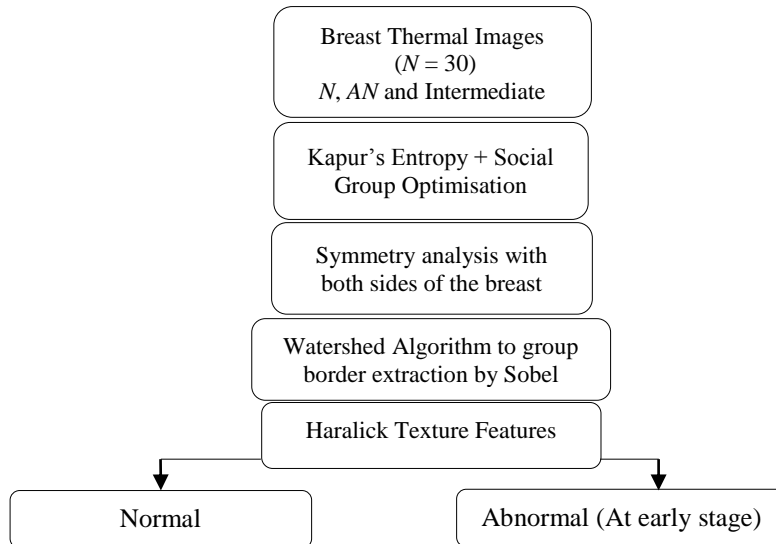


Fig. 1. Work flow of proposed scheme.

### 2.1. Kapur's entropy

Kapur's procedure was proposed in 1985 [13] to process pictures. Firstly, this technique was intended to obtain distinct gray level cases using its histogram. The benefits of this technique has recently attracted by many and have implemented to find solution for multiple segmentation problems. In this paper, this approach is considered to threshold the RGB scale ITI.

It decides thresholds  $T$  by maximizing the whole entropy of the image. Let,  $T = [T_1, T_2, \dots, T_{k-1}]$ , the image vectors. Further, the Kapur's function is put forth as;

$$J_{\max} = f_{Kapur}(T) = \sum_{j=1}^k H_j^C \quad \text{for } C \{1, 2, 3\} \quad (1)$$

Entropy of  $I_{RGB}$  is computed independently for R,G and B sections using given  $T$  value. The elaborate explanation of Kapur's is offered in [14-17].

### 2.2. Social group optimization

Satopathy and Naik proposed SGO [18,19] in 2016. SGO has two-phases;

#### Recovering period

Let  $X$  is the group of members, like  $i$  takes the value  $1, 2, \dots, N$  and  $D$ = search length with  $j$  is assigned from  $1, 2, \dots, D$ .

$$X_{new_{i,j}} = C * X_{old_{i,j}} + r * (gbest_j - X_{old_{i,j}}) \quad (2)$$

### Gaining period

The parameters are assigned the values,  $i = 1$  to  $N$ ;  $j = 1$  to  $D$ ,  $r = r_1=r_2=$  random number  $\sim U(0, 1)$

$$X_{new_{i,j}} = X_{old_{i,j}} + r_1 * (X_{i,j} - X_{r,j}) + r_2 * (gbest_j - X_{i,j}) \quad (3)$$

$$X_{new_{i,:}} = X_{old_{i,:}} + r_1 * (X_{r,:} - X_{i,:}) + r_2 * (gbest_j - X_{i,j}) \quad (4)$$

The preliminary constraints of the algorithm are allocated according to the work by Satapathy and Naik [18] and Naik et al. [19]. Further parameters are allocated as follows; the group size=25, the  $D =$  three, the number of run is assigned to be 1500 and terminating criterion will be  $J_{max}$  [20].

### 2.3. Symmetry examination

Breast evenness examination is a demonstrated practice to review the threat issue in the growth [21]. Usually, the tainted breast's amount, positioning and appearance will fluctuate from normal [22]. In order to analyze the abnormality and categorize the subjects: *i*) Edge recognition and binary picture making using Sobel, *ii*) Divide the picture into two equivalent sections and perform pixel count, *iii*) Classify the thermal images based on its pixel likeness. This procedure is simple and facilitates to categorize the considered ITI into normal, intermediate and abnormal.

### 2.4. Watershed segmentation

Marker driven Watershed (WS) approach presented by Roerdink & Meijster is adopted to extract the stroke region [23]. WS is grouping of Sobel border discovery procedure, marker driven morphological procedure and mining. The clear explanation of the adopted WS can be found in [24-29].

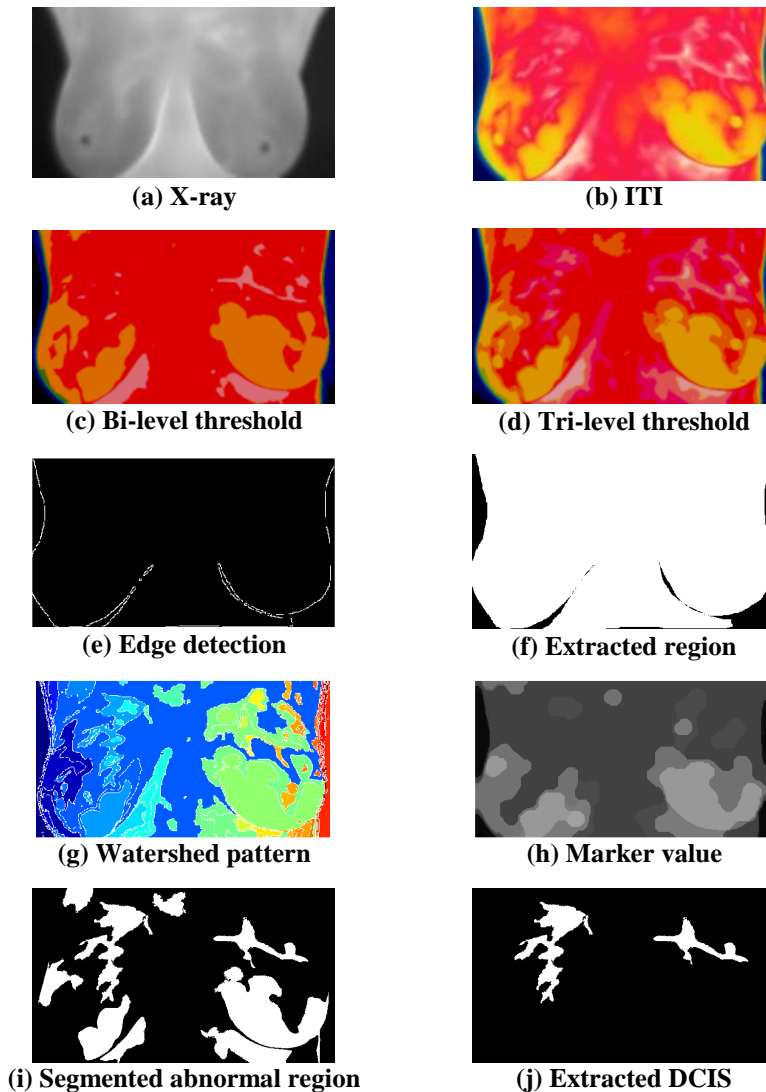
### 2.5. Implementation and Evaluation

In this paper, ten images of each case (Normal, Abnormal and Intermediate) are considered for the examination [30]. Feature extraction is a major part in attaining imperative details in test picture. To evaluate the spatial allocation of gray pixels, texture features are widely considered. It is performed by manipulating adjacent features at every tip of picture and inferring a set of arithmetical values. After extracting the abnormal section from the ITI, Haralick Texture Feature (HTF) is extracted [21]. Normally, the final image of the proposed procedure will be in the form of binary and the HTF extracts the features of the extracted pattern which has binary '1'. After extracting the HTF, it is possible to examine the severity of the ITI by simply analyzing the values. In future, the HTF can also be considered to design a classifier unit, which will help to classify the ITI as Benign or Malignant.

## 3. Results and Discussions

The Visual lab database consists of both the X-ray and thermal images recorded with image capturing device. The disease information available in X-ray is poor compared to ITI.

Figure 2 depicts the experimental results obtained for the chosen ITI. Figures 2(a) and (b) represent the X-ray and the ITI of abnormal case. After choosing the ITI, the pre-processing is implemented using SGO+Kapur's function based multi-level thresholding. Initially, a bi-level and tri-level thresholding is implemented to preprocess the image in order to enhance the visibility of the abnormality and the related outputs are described in Figs. 2(c) and (d) respectively. From this, it can be noted that, tri-level thresholding offers better image visibility compared with bi-level threshold. Hence, for the remaining images, tri-level threshold is considered. Figures 2(e) and (f) presents the results of edge detection procedures, which can be further, considered for the symmetry analysis with the help of the region properties (number of pixels existing in left and right breast region).



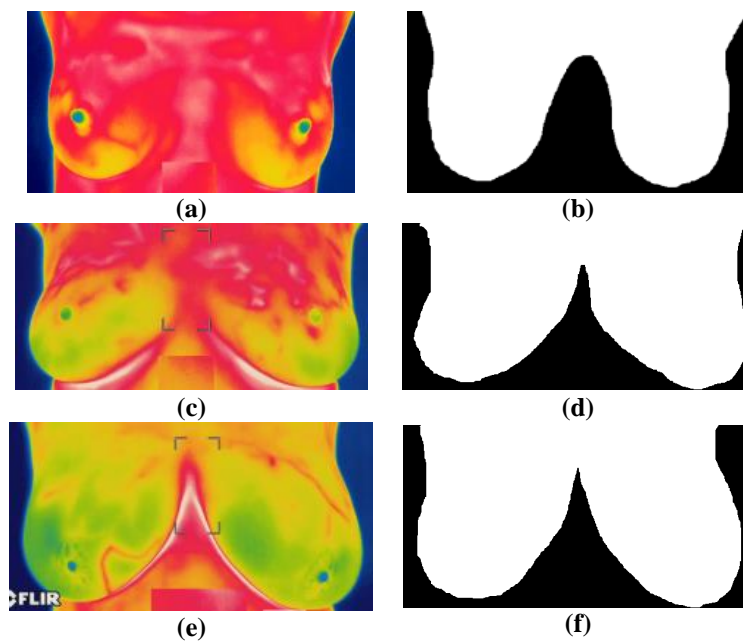
**Fig. 2. Experimental results for a chosen ITI.**

Finally, the post-processing is implemented with watershed algorithm, which can be used to mine the abnormal region from pre-processed picture. After extracting the DCIS, the seniority of the infected region is assessed by computing the HTF.

Alike process is repeated for the remaining pictures used in this work. Figure 3 depicts the results for normal image cases. Figures 3(a), (c) and (e) show the chosen ITI and Figs. 3(b), (d) and (f) show the extracted breast region. From this figure, it is observed that, the right breast region is approximately alike compared with the left region. Related method is repeated for all the images and based on its symmetry value; it is classified as normal, abnormal and intermediate as shown in Table I.

**Table 1. Evenness evaluation for chosen images**

Subject	Symmetry level in %	Forecast
Healthy	97.1764	Negative
Unhealthy	78.9015	Positive
Intermediate	94.8156	Neutral



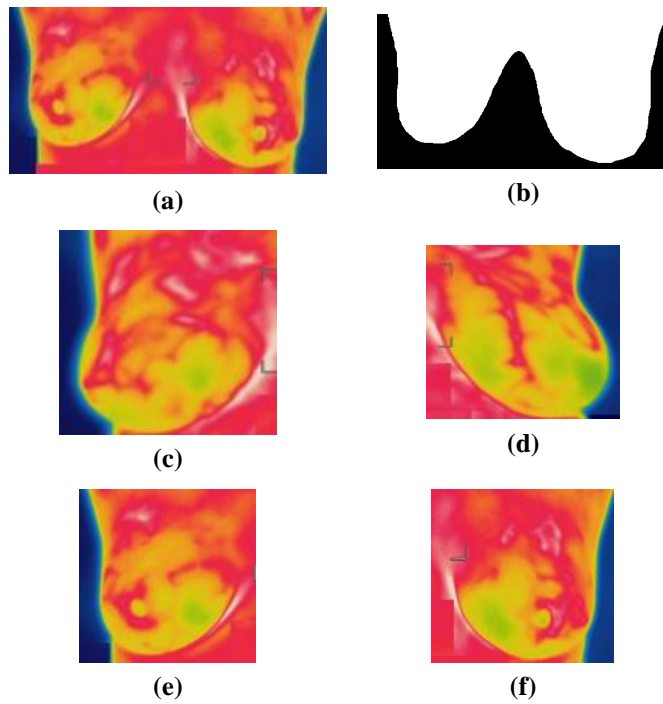
**Fig. 3. Normal breast images.**

Figures 4 and 5 present the outcome obtained for the abnormal breast image and the breast ITI having the DCIS.

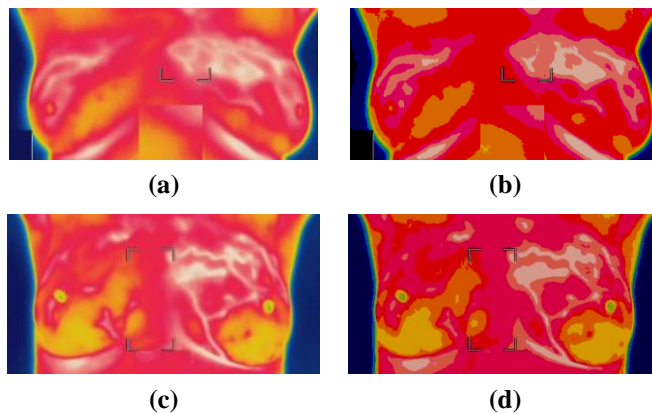
In these cases, the abnormality can be easily visualized with the ITI based on the breast un-symmetry and the abnormal blood vessel projections. Figure 4 shows the region wise analysis of the breast images in order to confirm its abnormality. Further, the mild infected regions are also extracted with the subjection of the considered algorithm. There early stage disease prognosis are detected in these

images since they are evident on ITI images rather than in other modalities. Figures 4(c) and (e) show the right regions and Figs. 4(d) and (f) show the left regions.

The pixels of these regions are then computed to categorize the image. Figure 5 shows the ITI having the DCIS and its pre-processed versions. The DCIS regions are then extracted with the proposed approach and its severity is then examined by computing the HTF as shown in Table 2. In future, the computed HTF can be considered to design a classifier system.



**Fig. 4. Abnormal breast images.**



**Fig. 5. Breast images having DCIS.**

**Table 2. Texture Features for the abnormal regions.**

Feature name	Normal	Abnormal	Intermediate
Homogeneity	0.8426	0.7064	0.7916
Correlation	0.9513	0.9482	0.9319
Energy	0.1107	0.6177	0.3518
Contrast	0.0775	0.1054	0.0815
Variance	0.5312	0.7881	0.7007
Entropy	0.1994	0.5693	0.3593
IMC1	-0.2517	-0.6427	-0.5434
IMC2	0.1139	0.7721	0.4052
Sum Average	1.1074	2.1178	2.1843
Sum Variance	2.1162	5.2861	3.1103
Sum Entropy	0.2986	0.6361	0.4175
MCC	0.3268	0.1795	0.1891

#### 4. Conclusions

This paper proposes a novel image processing procedure to examine the breast thermal images to discover the breast cancer. This technique implements a pre-processing and a post-processing approach to mine the abnormal regions from the considered image dataset. The pre-processing is implemented with SGO+Kapur's tri-level thresholding and the post-processing is implemented with watershed segmentation. Initially, an edge detection assisted symmetry analysis is proposed to categorize the considered ITI database as the normal, abnormal and intermediate. Finally, the extracted DCIS section is considered to extract the HTF values in order to assess its severity. Early disease diagnosis is possible in ITI since the slightest temperature variation reveals the state of the infection in the breast. The advantage of the infrared modality and the suitable image processing techniques applied in this work surfaces the disease condition even in early stage. Hence, the disease treatment can be advised to the patient well in advance when compared to other methods of diagnosis. The outcome of this paper substantiate that, proposed approach performs well for the images of Visual Lab dataset. As a forthcoming modality, this approach can be tested on the real clinical breast thermal images obtained from the hospitals.

#### Nomenclatures

$D$	Search length
$gbest$	Global best
$I_{RGB}$	Image in RGB
RGB	Red green Blue channel
$r, r_1, r_2$	random number
$T$	thresholds
$X$	group of members

#### Abbreviations

DCIS	Ductal Carcinoma In Situ
HTF	Haralick Texture Feature
ITI	Infrared Thermal Imaging
MRI	Magnetic Resonance Imaging
SGO	Social Group Optimization



## References

1. Patel, B.C.; and Sinha, G.R. (2014). Abnormality detection and classification in computer-aided diagnosis (CAD) of breast cancer images. *Journal Medical Imaging Health Informatics*, 4(6), 881-885.
2. Acharya, U.R.; Ng, E.Y.-K.; Tan, J.H.; and Sree, S.V. (2012). Thermography based breast cancer detection using texture features and support vector machine. *Journal of Medical Systems*, 36(3), 1503-1510.
3. Sree, S.V.; Ng, E.Y.-K.; Acharya, U.R.; and Faust, O. (2011). Breast imaging: A survey. *World Journal of Clinical Oncology*. 2(4), 171-178.
4. Bejnordi, B.E.; Balkenhol, M.; Litjens, G.; Holland, R.; Bult, P.; Karssemeijer, N.; and van der Laak, J.A.W.M. (2016). Automated detection of DCIS in whole-slide H&E stained breast histopathology images. *IEEE Transactions on Medical Imaging*, 35(9), 2141-2150.
5. Srivastava, S.; Sharma, N.; Singh, S.K.; and Srivastava, R. (2014). Quantitative analysis of a general framework of a cad tool for breast cancer detection from mammograms. *Journal of Medical Imaging and Health Informatics*, 4(5), 654-674.
6. Lee, J.M.; Halpern, E.F.; Rafferty, E.A.; and Gazelle, G.S. (2009). Evaluating the correlation between film mammography and MRI for screening women with increased breast cancer risk. *Academic Radiology*, 16(11), 1323-1328.
7. Zadeh, H.G.; Haddadnia, J.; Ahmadinejad, N.; and Baghdadi, M.R. (2015). Assessing the potential of thermal imaging in recognition of breast cancer. *Asian Pacific Journal of Cancer Prevention*, 16(18), 8619-8623.
8. Sutha, M.J.; and Dhanaseelan, F.R. (2015). An efficient method for detection of breast cancer based on closed frequent item sets mining. *Journal of Medical Imaging and Health Informatics*, 5(5), 987-994.
9. Raja, N.S.M.; Rajinikanth, V.; Fernandes, S.L.; and Satapathy, S.C. (2017). Segmentation of breast thermal images using Kapur's entropy and hidden Markov random field. *Journal of Medical Imaging and Health Informatics*, 7(8), 1825-1829.
10. Vishnupriya, R.; Raja, N.S.M.; and Rajinikanth, V. (2017). An efficient clustering technique and analysis of infrared thermograms. *Proceedings of Third International Conference on Biosignals, Images and Instrumentation (ICBSII)*, 1-5.
11. Silva, L.F.; Saade, D.C.M.; Sequeiros, G.O.; Silva, A.C.; Paiva, A.C.; Bravo, R.S.; and Conci, A. (2014). A new database for breast research with infrared image. *Journal of Medical Imaging and Health Informatics*. 4(1), 92-100.
12. Visual Lab DMR (2018). Thermal imaging. Retrieved October 5, 2017, from <http://visual.ic.uff.br/dmi/prontuario/home.php>
13. Kapur, J.N.; Sahoo, P.K.; and Wong, A.K.C. (1985). A new method for gray-level picture thresholding using the entropy of the histogram. *Computer Vision, Graphics, and Image Processing*, 29(3), 273-285.
14. Rajinikanth, V.; Raja, N.S.M.; and Kamalanand, K. (2017). Firefly algorithm assisted segmentation of tumor from brain MRI using Tsallis function and Markov random field. *Journal of Control Engineering and Applied Informatics*, 19(3), 97-106.
15. Manic, K.S.; Priya, R.K.; and Rajinikanth, V. (2016). Image multithresholding based on Kapur/Tsallis entropy and firefly algorithm. *Indian Journal of Science and Technology*, 9(12), 1-6

16. Rajinikanth, V.; Raja, N.S.M.; and Satapathy, S.C. (2016). Robust color image multi-thresholding using between-class variance and cuckoo search algorithm. *Advances in Intelligent Systems and Computing*, 433, 379-386.
17. Satapathy, S.C.; Raja, N.S.M.; Rajinikanth, V.; Ashour, A.S.; and Dey, N. (2016). Multi-level image thresholding using Otsu and chaotic bat algorithm. *Neural Computing and Applications*, 29(12), 1285-1307.
18. Satapathy, S.; and Naik. A. (2016). Social group optimization (SGO): a new population evolutionary optimization technique. *Complex and Intelligent Systems*, 2(3), 173-203.
19. Naik, A.; Satapathy, S.C.; Ashour, A.S.; and Dey. N. (2016). Social group optimization for global optimization of multimodal functions and data clustering problems. *Neural Computing and Applications*, 30(1), 271-287.
20. Rajinikanth, V.; Satapathy, S.C.; Fernandes, S.L.; and Nachiappan, S. (2017). Entropy based segmentation of tumor from brain MR images - A study with teaching learning based optimization. *Pattern Recognition Letters*, 94, 87-95.
21. Haralick, R.M.; Shanmugam. K.; and Dinstein, I. (1973). Textural features for Image classification. *IEEE Transactions on Systems, Man, and Cybernetics*. SMC-3(6), 610-621.
22. Manickavasagam, K.; Sutha, S.; and Kamalanand, K. (2014). Development of systems for classification of different plasmodium species in thin blood smear microscopic images. *Journal of Advanced Microscopy Research*. 9(2), 86-92.
23. Shanthakumar, P.; and Kumar, P.G. (2015). Computer aided brain tumor detection system using watershed segmentation techniques. *International Journal of Imaging Systems and Technology*, 25(4), 297-301.
24. Rajinikanth, V.; and Satapathy, S.C. (2018). Segmentation of ischemic stroke lesion in brain MRI based on social group optimization and fuzzy-Tsallis entropy. *Arabian Journal for Science and Engineering*, 43(8), 4365-4378.
25. Rajinikanth, V.; Dey, N.; Satapathy, S.C.; and Ashour, A.S. (2018). An approach to examine magnetic resonance angiography based on Tsallis entropy and deformable snake model. *Future Generation Computer Systems*, 85, 160-172.
26. Raja, N.S.M.; Fernandes, S.L.; Dey, N.; Satapathy, S.C.; and Rajinikanth, V. (2018). Contrast enhanced medical MRI evaluation using Tsallis entropy and region growing segmentation. *Journal of Ambient Intelligence and Humanized Computing*, 1-12.
27. Raja, N.S.M.; Sukanya, S.A.; and Nikita, Y. (2015). Improved PSO based multi-level thresholding for cancer infected breast thermal images using Otsu. *Procedia Computer Science*, 48, 524-529.
28. Varsha Shree, T.D.; Revanth, K.; Raja, N.S.M.; and Rajinikanth, V. (2018). A hybrid image processing approach to examine abnormality in retinal optic disc. *Procedia Computer Science*, 125, 157-164.
29. Dey, N.; Rajinikanth, V.; Ashour, A.S.; and Tavares, J.M.R.S. (2018). Social group optimization supported segmentation and evaluation of skin melanoma images. *Symmetry*, 10(2), 51.
30. Rajinikanth, V.; Raja, N.S.M.; Satapathy, S.C.; Dey, N.; and Devadhas, G.G. (2017). Thermogram assisted detection and analysis of Ductal Carcinoma In Situ (DCIS). *Proceedings of International Conference on Intelligent Computing, Instrumentation and Control Technologies (ICICT)*, Kannur, India.